

Effect of Losartan drug on pulmonary fibrosis induced by Bleomycin in experimental rats

Mahdi m.Th.^{1*}, maha K. Ibrahim²

¹Department of Basic science, College of nursing, Thi-Qar University, Iraq

²Department of Biology, College of science, Basra University, Iraq

Abstract: The present study investigated the protective effect of losartan (Angiotensin II inhibitor AT1) administration against bleomycin-induced pulmonary fibrosis in adult male rats. A total of 40 male adult albino rats (*Rattus norvegicus*) weighing from 200-300 gm each, were divided into four groups of (10) animals each. The first group received a daily intraperitoneal (i.p) injection of vehicle normal saline (0.5ml/animal, daily to end experiment), and served as control group. Animals in the second, third and fourth groups were administrated i.p. with bleomycin (15mg/kg\3times weekly for 3 wks), losartan (50mg/kg orally daily to end experiment) and losartan a combination with bleomycin simultaneously to end experiment, respectively.

The present study, declared that the biochemical results determined the levels of Superoxide dismutase (SOD), Glutathion peroxidase (GSHpx) and Hydroxyproline(HYP) content in blood serum of animals. Where after oral administration of losartan in combination with bleomycin, showed that losartan significantly increase SOD $P < 0.008$ and GSHpx $P < 0.001$ levels, and decreased HYP $P < 0.001$ contents in blood stream of the rats in comparison with bleomycin group. conversely, study showed After intraperitoneal injection of bleomycin alone, decreased level of SOD, GSHpx and increased of HYP content in blood serum of rats in comparison of control group. On the other hand, microscopical observations clarified that bleomycin injection showed that inflammatory cells infiltration and fibrotic scores were more prominent, in addition to that, atelected alveoli with damage to lung architecture as well as collagens deposition around patches of alveoli and peribronchioles in the model group compared to the control group, oral administration of losartan in combination with bleomycin, showed marked attenuated the severity of bleomycin –induced pulmonary fibrosis, where identified by reduce the inflammatory cells infiltration whether intraalveolar or interalveolar septa.

This investigation has clearly identified the importance role of losartan as inhibitor factor on pulmonary fibrosis induced by blm, therefore the findings may be offer one of therapeutic strategy to prevent the lung fibrosis in experimental model.

Keywords: Losartan, pulmonary fibrosis, Bleomycin.

Introduction

Pulmonary fibrosis (PF) is a progressive interstitial lung disease with a high mortality rate and no effective treatment to date^{1,2}. The progression of pulmonary fibrosis results in the widening of interstitial matrix, and eventually in the compression and destruction of normal lung parenchyma³. This disease characterized by loss of lung's architecture through increased epithelial cell apoptosis and abnormal wound repair, lead to the formation of fibroblast –myofibroblast foci and an extracellular matrix deposition^{4,5}. Experimental lung fibrosis induced by bleomycin is a well studied model of fibrogenesis supported by ample literatures. This model of pulmonary fibrosis resemble that seen in humans and had been used to assessed the

effect of potential therapeutic agents⁵. It has been used successfully to treat a variety of malignancies including ;squamous cell carcinoma of testis ,head , neck ,cervix , esophagus germ cell tumors and both Hodgkin , non-Hodgkin lymphoma. The limitation of bleomycin for lifethreating interstitial pulmonary fibrosis (also called fibrosing alveolitis) in up to 10 percent of patients receiving the drugs. Specific treatments for fibrotic lung diseases are not yet available ,and they are limited to the control of inflammatory events in the lung with the expectation that prevention of inflammation might delay the progression of fibrotic events⁶. The hormone angiotensin 11 is produced primarily in the lung and serve as a putative induce of TGF- β expression , it may not only up-regulate TGF- β , but expression ,but may also alter TGF- β receptors in various models of tissue fibrosis (7). Indeed the anti-fibrotic activity of angiotensin receptors blockers ,such as losartan may significantly contribute to their therapeutic benefit in patients with cardiovascular and renal disease⁷. It is known that losartan, a selective AT1 receptor antagonist ,inhibits the proliferation of human lung fibrotic fibroblast induced by ANG11 in vitro^{8,9}. Moreover, losartan inhibits the collagen deposition in the rat model of bleomycin induced pulmonary fibrosis⁸. It has been reported that prostoglandins , is a potent inhibition of fibroblast differentiation. At large, from the a mention above ,administration of losartan lead to, increase PGE and decrease ANG11,so that both of these two process together lead to an inhibition of fibroblast proliferation and collagen synthesis. Therefore, the main objective of this study was investigated to clarified the impact of losartan on the induction of pulmonary fibrosis in rats.

Experimental Animals

Male wisteralbino Wister rats (*Rattus norvegicus*) weighing 200-250 gm were obtained from animal center of Thi-Qar university \college of science . All animal were allowed to take food and received tap water *ad libitum*,temperature (22 \pm 3) with an alternating cycle of 12-h light and *dark*.

Animals were equally distributed into four groups (10 rats) in each experiment;

Group1; Control group, the animals received sterile saline solution 0.5ml \animal \daily i.p to end experiment.

Group2; Induction group, the animals received bleomycin 15mg\kg \i.p. three times weekly for3wks.

Group3; Animals received losartan at adose 50mg\kg daily for end experiment.

Group4; Animals received bleomycin and losartan together simultaneously at doses, periods and administration similar to groups 2 and 3 so that mentioned above.

The dose level and schedule were based on previous studies^{7,8}. The animals were starved over night for 12hrs. Before blood was collected, rats were anaesthetized with chloroform and venous blood samples were collected by direct heart puncture into sterilized tubes (without anticoagulant to separate the sera and then keeping in freezer to determinate some biochemical parameters like SOD ,GSHpx and HYP, and (with anticoagulant) to procedure rapid hematological examination.

Biochemical parameters

Measurement of GSHpx,SOD and HYP

The serum glutathione peroxidase (GSHpx),superoxide dismutase (SOD) and hydroxyproline (HYP) were measured on the basis of the instruction of kit for each ,that is, Cusabio Eliza kit, catalo no. CSB-E 121144r. Briefly use a human serum tube or aserum separater tube(SST) and allow samples to clot for 30 minutes before centrifugation for 15 minutes at 3000 rpm remove serum and assay immediately or aliquot and store samples at-20 c⁰ until required samples were read to absorbance at 450 nm.

Histophthological examination

Lung tissue samples were obtained from sagittle slices of the lungs ,were fixed in 10% formalin for²⁴ and then washed –dehydrated-cleared and embedded in paraffin²³ ,sections about 4 μ m thickness was cutting stained with hematoxylin -Eosin for microscopic examination. The histological changes were evaluated by observe of lesions microscopically.

Statistical analysis

All values were expressed as mean \pm SD with 95% confidence intervals (CI) of experiment statistical analysis of variance (ANOVA) followed when differences were significant. Differences between groups were testing using the paired students T-test .Differences were considered statistically significant at P<0.05²⁴.

Results

Biochemical parameters

Table 1:- Effect of losartan on superoxide (SOD), glutathione peroxidase (GSHpx) and hydroxyproline (HYP) in blood serum of rats with pulmonary fibrosis (mean±S.D).

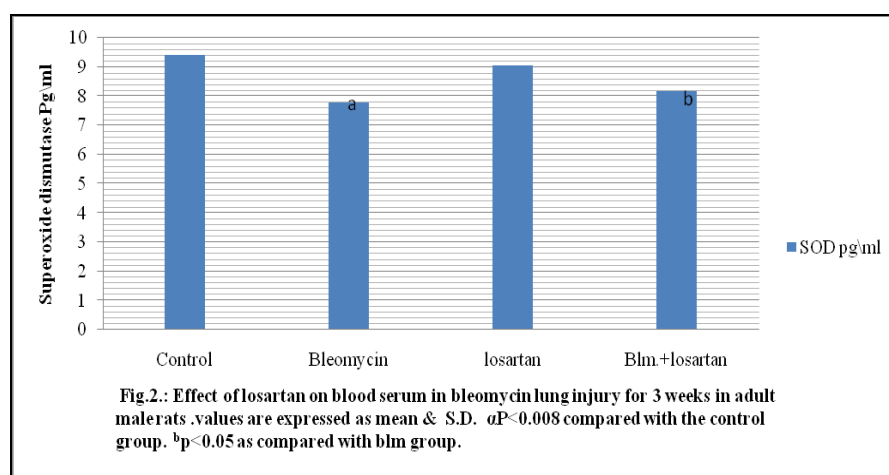
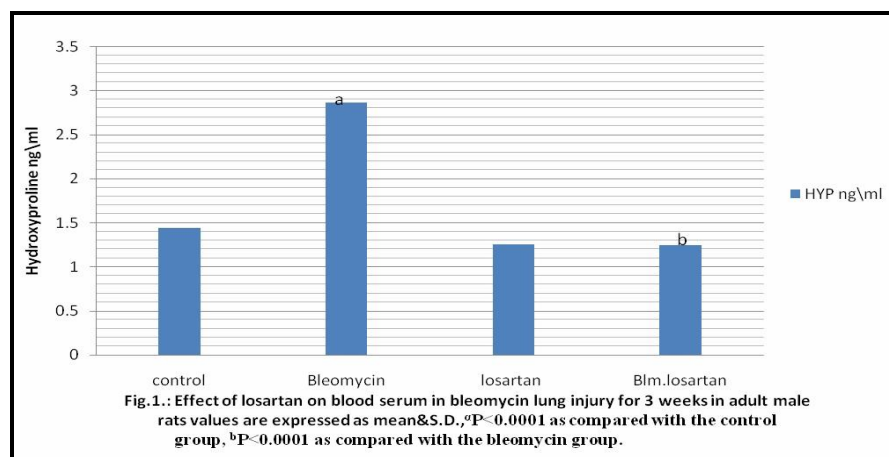
Groups	SOD Pg/ml	GSHpx mIU/ml	HYP µg/ml
Control	9.42±1.08	33.18±3.44	1.44±0.204
Bleomycin	7.77±0.644 ^a	17.04±1.52 ^a	2.86±0.125 ^a
Losartan	9.06±0.78	28.63±1.20	1.25±0.185
Blm+losartan	8.17±0.969 ^b	29.06±7.814 ^b	1.24±0.342 ^b

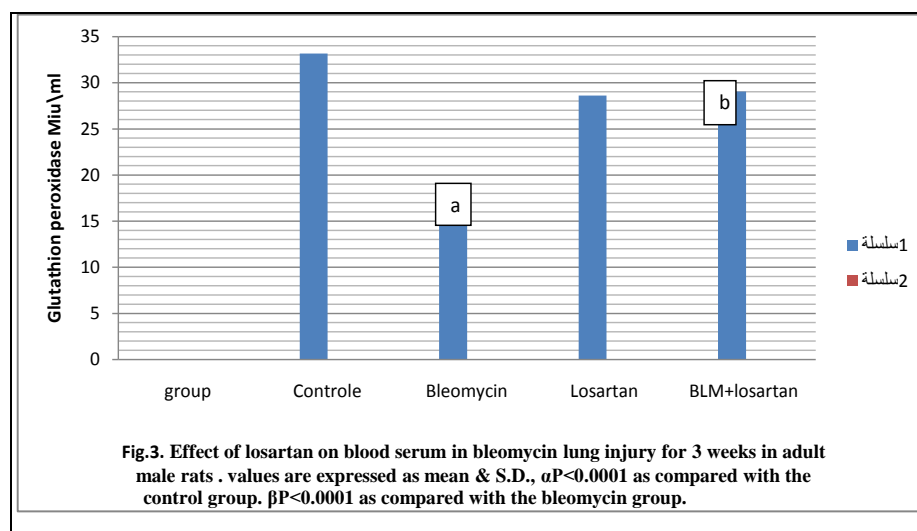
Hyp; ^ap<0.0001 vs.control group, ^bp<0.0001vs.blm group.

SOD; ^ap<0.008 vs. control group , ^ap<0.05 vs.blm group.

GSHpx; ^ap<0.001 vs. control group, ^bp<0.02 vs. blm group.

Results of recent study showed, effect of bleomycin injection on Hydroxyproline content in blood serum were significantly increase in rats with lung fibrosis compared to control group P<0.0001 .This rise were markedly inhibited by administrate of losartan in combination with bleomycin p<0.0001(table1and fig.1) in compared to bleomycin group. Effect of losartan on antioxidant enzymes include SOD and GSHpx in blood serum of rats with pulmonary fibrosis ,showed a depletion of SOD activities in the blood serum of Bleomycin group , where SOD activity was significant decrease compared with the control group at P<0.008,that depletion of SOD activity ,after administrate of losartan with bleomycin significantly prevented the depletion of SOD activity P<0.05(table 1and fig.2) . Furthermore, bleomycin treatment produced a significant decrease in blood serum GSHpx level at P<0.0001,in rats with pulmonary fibrosis , but use losartan with bleomycin caused significant attenuated of the bleomycin –induced pulmonary fibrosis in the GSHpx level P<0.02 (table 1and fig.3).





Histopathological findings

Lungs sections of normal rats showed the respiratory portions composed of pocket like sacs called alveoli ,also each neighboring alveoli separated by walls known as interalveolar septum with normal alveolar spaces and normal alveolar thickening septa (fig.4) .The lungs of rats treated with bleomycin showed alveolar wall thickness ,areas of inflammatory infiltration cells mainly lymphocytes ,neutrophils and fibroblasts ,and collapsed alveoli with marked damage in lung architecture ,in addition ,there was an excessive amount of collagen deposited around some areas of alveoli and bronchioles (fig.5). Observation on lungs related to rats treated with both bleomycin and losartan, showed declared marked –suppression of inflammatory cellular evidenced by reduced interstitial infiltrations , less collagen deposition and less thickening in septal walls ,also these septa appeared more wide (fig.6)

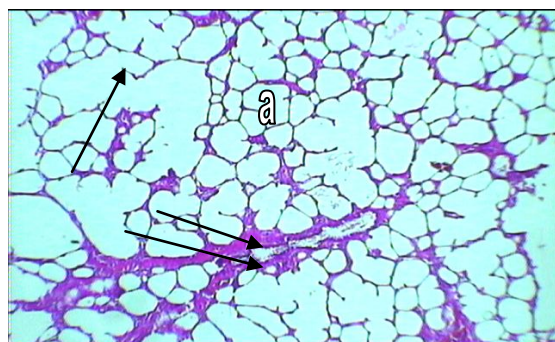


Fig.4:- Section in the Normal lung parenchyma from saline treated rats (control). Showing alveolar spaces (a) and alveolar septum (arrow), branch of respiratory bronchiole (two arrow).

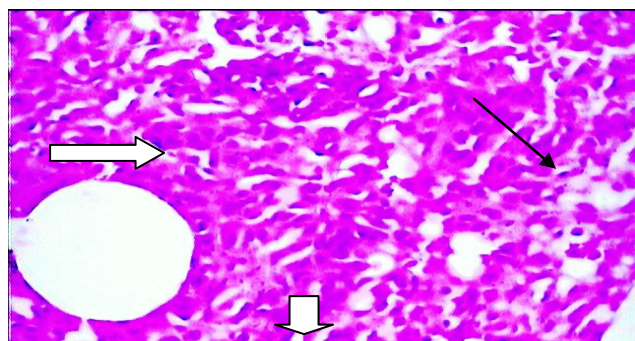


Fig.5:- Section in the lung of rats treated with bleomycin marked thickening in alveolar septa, numerous mononuclear inflammatory cells and with deposition collagen fibers (arrow) ,collapsed alveolar narrow spaces (thick arrow) ,and markedly proliferation of fibroblasts after 21 days bleomycin injection, partial or complete obliteration of alveolar spaces (head thick arrow).

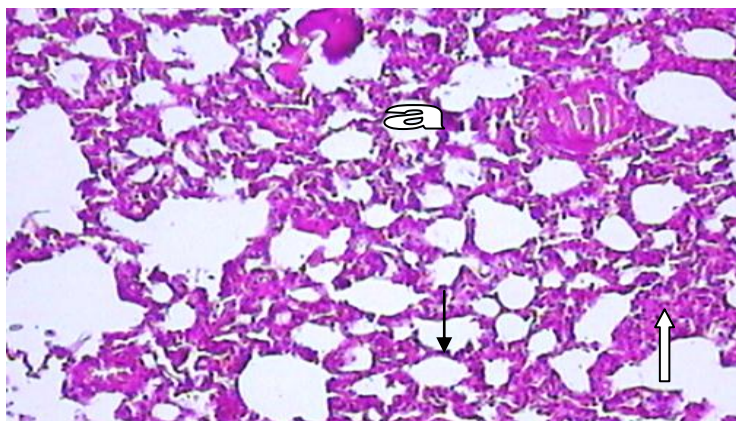


Fig.6:- Section in the lung of rats treated with bleomycin-Losartan, marked reduction showing in mononuclear inflammatory cells(whit arrow), reduction of thickening the of the alveolar septa(black arrow), more patent alveolar spaces (a) and reduction of collagen deposition compared to bleomycin group.

Discussion

To date, controversy exists whether blockad of losartan (AT11) can attenuate the development of lung fibrosis in animals models and delayed its progression ,where ,losartan inhibits angiotensin type 11 which lead to decrease TGF- β production, followed by decrease pulmonary fibrosis progression (14,15).

In the present experiment ,we examined the effect of losartan on pulmonary fibrosis induced by intraperitoneal injection with bleomycin (15mg/kg). Bleomycin could result an increased AGT11 concentration in lung tissues¹⁶. In fact,AGT11 also resulted in the production of free radicals , in the model of myocardial infarction , liver fibrosis ,renal injury ,and AT1 receptor blockers could prevent the progression of he above mentioned organ injury induced by free radicals¹⁷. However, the present study showed that bleomycin exposure caused significant increase HYP and decrease in anti-oxidant enzymes activities in blood serum in rats with pulmonary fibrosis . Which where attenuated by losartan ,indicated that the effect of losartan lung fibrosis was associated with free radicals scavenging and antioxidant activity. The study shows that losartan significantly decrease lung inflammatory infiltration. After bleomycin exposure, the inflammatory effects of AT1 receptors blockade has been reported in previous studies^{18,19}. Our findings; agreed with those²⁰ who showed that condesartan attenuated hydroxyproline in lung tissue induces by bleomycin injection. in contrary, decrease of antioxidant enzymes SOD ,GSHpx . Our study confirmed that losartan is effective in reduce lung fibrosis induced by bleomycin.

Histological results referred that administration of bleomycin increase collagen deposition and histological changes in lung tissue with high degree of fibrosis ,This was in agreement with findings reported previously^{20,21}, namely, bleomycin was increased hydroxyproline level in blood serum in rats with pulmonary fibrosis ,administration of losartan resulted in significant reduction in the marked HYP concentration and reduced the increase in lung coefficient without reaching those of control animals. In the current study, antioxidant enzymes were decreased in bleomycin treated rats while treatment with losartan induced a significant increased in antioxidant enzymes compared to bleomycin group. In agreement,HYP and antioxidant enzymes(SOD ,GSHpx) expression were up regulated in fibrotic lung²². Whereas ,losartan reduced the HYP level in bleomycin-induced lung injury –treated rats. Additionally, histological examination showed that losartan could inhibit the progression of lung fibrosis induced by bleomycin in adult albino rats (rattus norvegicus) as previously described^{13,16}.

In conclusion , data , from this study suggest that protection effect of losartan against bleomycin – induced lung injury could be due to its antioxidant activity , as well as ,data proposed that the potential for angiotensin 11 receptor blockers as a therapeutic strategy in patient with pulmonary fibrosis may be beneficial . Consequently , the present study results that the losartan ameliorating effect of pulmonary fibrosis induced by bleomycin in rats, and support the harmful role of AT1 receptors in mediating the effects of ANG11 in bleomycin –induced lung injury and fibrosis in rats.

References

1. Bjoraker J.A.,Ryu JH.,and Edwin m.k.; (1998);Prognostic significance of histologic subsets in idiopathic pulmonary fibrosis. *Am J Respir crit med*; 157,190-203.
2. Douglas ww,Ryu J.H.,Schroeder D.r.; Idiopathic pulmonary fibrosis : (2000);Impact of oxygen and colchicine,prednisone or no therapy on survival . *Am J Respir crit care med*:161,1172-1178.
3. Hong weiyao ,Jain Ping zhu,mag hui zhao and yuan lu ; (2006); Losartan attenuates blm-induced pf in rats ; *Respiration* ; 73;236-242 .
4. Fellrath J.M., and Du Beis R.M.; (2003);Idiopathic fibrosis cryptogenic fibrosing alveolitis . *Clin Exp med* ;); 3:65-83.
5. Molina Molina M ,A Serrano-mollar, O Bulbena , L. Fernandez- zabelegui,D closo , A marin-Arguedas ,A Toorego , C picaado, and yanbet ; (2012); Losartan attenuates blm-induced lung fibrosis by increase PGE2 synthesis .*Thorax* ;bl; 61;604-610.
6. Kroegel C., Mock B., Hengst , and Reissing A : (2004);In terfero gamma-Ib;Theraputic option in advance IPF ? *Respiration* , 71;656-657.
7. Keogh K. A., Standing J. , Kane G.c., Terzic A . and limper A.H., ; (2005);Angiotensin 11 antagonist fails to ameliorate blm-induced pulmonary fibrosis in mice . *Eur Respir J* ; 25 ;708-714.
8. marshal R.D., McAnulty R.J. and Laurent G; (2000);Ang 11 is mitogenic for human lung fibrosis via activation of the type 1 receptor .*Am J respire crit care med* ; 161;1999-2004.
9. Barok Z., Gillissson A ., Buhlr R ; (1991); Augmentation of functional PGE levels on the respiratory epithelial surface by aerosol administration of PGE .*Am.Rev Respire Dis*;144;1080-4.
10. Serrano –maller A , Closa D ., Cortijo J ; (2002);P-selectin upregulation in blm-inducced lung injury in rats ; effect of N-acetyl-L-cysteine .*Thorax*;57;629-34.
11. Cartigo J. Cerda-Nicolas M. and Serrano A., (2001) ;Attenuation by oral N-acetyl cystein Blm – induced lung injury in rats.*Eur respire J* ; 17;1228-35.
12. Aygul Guset , Mrthact G., Ahmed G., Hasan A., Naci M ., Ayhan G., and tolga G., (2012);Infliximab attenuates activated charcoal and polyethylene glycol aspiration –induced lung injury in rats; *Experimental lung research* ; 38;146-156.
13. Ahmed M. Attia and Hoda M., Nasr ; (2009); Evaluation of protective effect of Omega-3 fatty acids and selenium on paraquat intoxicated rats; *Slova J. Anim. Sci.*, 42(4):180-187.
14. Wang R., Ibarra –Sunga O , Verlinski L., Pick R., and Uhal BD.; (2000);Abregatein of blm-induced epithelial apoptosis in lung fibrosis by captopril or by caspase inhibitor . *Am J physiology cell moll physiol* ; 179;L143-15.
15. Molteni A , Mulder JE., Coben EF ., Ward Wf., Fish BL., Tayler JM., Wolfe LF., Brizio–molteni L .and Vene P.,(2000); Control of radiation –induced pneumopathy and lung fibrosis by ACE inhibitors and an AGT11&1receptor blocker , *INT J radial Biol.*;176;623-532.
16. Marshal R.P., Gobike P., Chambers R.C., Howdl D.c., Bottorns S.E., Unger T., McAnnulty R.J., and lurent G.J., ; (2004);AGT11 and the proliferative response to acute lung injury .*AM J physio of lung cell mol physiol* ; 286;L156-1164.
17. Friedmon S.L., ;The answer :AG11 , th question : (2004) what do inflammation ,Oxidant stress and fibrogenesis have in commom ?*J heptol*;40;1050-1052.
18. Otsuka M. ,Tokahashi H., Shiraterim ;(2004) ; reduction of blm-induced lung fibrosis by condesartan cilexetil,an ANG11 type 1 receptor antagonist;*Thorax* .; 59;31-8.
19. Grafe M., Auch Schwelk W., and zakrzewicza; (1997);ANG 11-induced leukocytes adhesion on human coronary endothelial cells mediated by E-selectin ; *Cire Res* ; 81;804-11.
20. A El-medany ,H .Hagara ,M. Moursib,R.At mohammed F. , El-Rakhawys and G-El-mednay ;attenuation of blm – induced lung fibrosis in rats by mesna ,*EUR J pharmacol*,2005509(1);61-70.
21. Gli,S.,Pi,z.,Xu., C.Liu ,X.,Wang B.,Liao and y.yin; (2008);signal transducer and activator of transcription 6expression in blm – induced lung fibrosis in rats .*J chin clin med* , 3(9);481-487.
22. Rbort v., Heymes C., Silvestra J., Sabr –A., Swynghedauw and c-delcayle; (1999) Angiotensin AT1 receptor subtype as a cardiac target of aldosteron :Role of aldosteron salt –induced fibrosis ,*hypertension* ,33(4);981-986.
23. Aly mohammed Ahmdi ; (2005); Inhibition of bleomycin –induced lung damage in mice by curcumin;*The Egyptian Journal of histology*; Vol .28 , No2 ; 211-220.
24. Sabine Landau and Brian S.,Everitt (Edit). *A Handbook of statistical Analyses using Spss* ,Chapman and Hall\CRC, Washington.,2004.
